

SOME HISTOLOGICAL OBSERVATIONS ON OVARY AND SPLEEN OF HEAT-STRESSED LAYING HENS TREATED WITH ANTIOXIDANTS

Abd El-Hack, M.E.; Sh.M. Sonbol ; A. A. Askar and Kh. M. Mahrose
Poultry Dept., Fac. Agric., Zagazig Univ., Zagazig, Egypt.

ABSTRACT

A total number of 40 of Bovans laying hens at 42 weeks of age were randomly distributed into five experimental groups and treated with different levels of vitamins A; E and selenium to investigate their effects on some important tissues (ovary and spleen) of laying hens under heat stress conditions.

Histopathological examination revealed that ovaries of birds received diet containing 0.0 mg/kg diet of vit. E with 0.2 mg/kg diet of selenium were moderately activated with an increase of primary oocytes. However, the spleen showed moderate hyperplasia of the white pulp and focal thickening of the splenic capsule. Birds fed on diet containing 1000 IU/kg diet of vit. A and 0.0 mg/kg diet of vit. E showed moderate activity of ovarian follicles with hypercellular stroma. The spleen showed hyperplasia in the lymphoid cells of white pulp and an increase in the reticuloendothelial cells (REC). Birds that received diet containing 16000 IU/kg diet of vit. A showed slight increase in the primary and growing ova as compared to control. The spleen revealed moderate hyperplasia in the white pulp area. Moreover, birds received diet containing 16000 IU/kg diet of vit. A, 0.0 mg/kg diet of vit. E and 0.2 mg/kg diet of selenium showed active ovaries containing variable sized ova and numerous blood capillaries. The spleen showed hyperplasia of the white pulp area.

It is concluded that the addition of vitamins A; E and Se to layer diets activated the ovarian function and enhanced the immune response of laying hens under heat stress conditions.

INTRODUCTION

There are many stressors affecting poultry production, hot environment is the most effective one of these stressors. The resultant heat stress comes from the interactions among air temperature, humidity, radiant heat and air speed, where the air temperature plays the major role (Lin *et al.*, 2006). The optimum temperature for performance is likely to be 18 to 22°C for laying hens (Charles, 2002). In the hot environment, chickens grow and lay by exerting an effort to maintain their body temperature within a normal range, to cope with stress responses and to ensure their visceral organs function under a heavier heat burden. Stress response mainly associated with the activation of hypothalamo-pituitary-adrenal (HPA) axis and orthosympatic nervous system, which aggravate the detrimental effect of high body temperature (Lin *et al.*, 2006). High environmental temperature in summer season in Egypt

causes negative effects on laying hens; it affects adversely the performance especially growth rate, egg production and egg quality traits; in addition to negative effects on the physiological traits such as blood levels of proteins, lipids, hormones and enzymes, as well as, the immunity responses of laying hens (Grizzle *et al.*, 1992; Mahmoud *et al.*, 1996; Sahin and Kucuk, 2001 and Mashaly *et al.*, 2004).

Many trails were conducted to alleviate the effect of high environmental temperature on laying hens. Vitamins and electrolytes were supplemented in layer diets to alleviate the negative effects of heat stress (Puthongsiriporn *et al.*, 2001). Several workers reported a beneficial effect of vit. A supplementation on the biological performance of stressed laying hens as a result of many important functions of vit. A in the body including vision, differentiation of epithelial cells and reproduction (McDowell, 1989; Sahin *et al.*, 2002 and Lin *et al.*, 2002). Also, Butera and Kraowka (1986) reported that vitamin A deficiency had detrimental effects on the avian immune system functions.

Vitamin E is known to be a lipid component of biological membranes and is known to be a major chain-breaking antioxidant (McDowell, 1989). Tengerdy (1988) suggested that vitamin E supplementation is very effective for animals through reducing the negative effects of corticosterone induced by heat stress. Chickens, cannot synthesize vitamin E; therefore, vitamin E requirements must be met from dietary sources (Chan and Decker, 1994).

Selenium is an essential trace element because it plays an effective and important role in the protection of cells against the damage that originates from free radicals (Rayman, 2002 and Daniels, 2004). The role of selenium in biological systems has been associated with its antioxidant activity (Schwarz and Foltz, 1957). Selenium and vitamin E display a synergic antioxidant activity in the prevention of lipid peroxidasis (Sahin and Kucuk, 2001 and Sahin *et al.*, 2002). Adequate levels of selenium and vitamin E are important not only to prevent their deficiency signs but also to preserve the organelles responsible for building antibodies and defense mechanisms against diseases and other stresses (Yu, 1994 and Spears, 1999).

Studies on the specific ability of extra supplementation of vitamins A; E and Selenium for heat stress alleviation and their benefits to some important tissues (ovary and spleen) of laying hens under heat stress are very limited. Therefore, some of the influences of vitamins A; E and selenium and their interaction on the histological feature of the ovary and spleen were evaluated in this study.

MATERIALS AND METHODS

The present study was carried out at Poultry Research Farm, Department of Poultry, Faculty of Agriculture, Zagazig University, Zagazig, Egypt, during the period from July to September 2008 (3 months).

A total number of ۴۰ of Bovans laying hens at ۴۲ weeks of age was randomly distributed into five experimental treatment groups as follows:

Treatment	Vit. A (IU/kg diet)	Vit. E (mg/kg diet)	Se (mg/kg diet)
T ^۱	.	.	.
T ^۲	.	۰.۰۰	۰.۰۲۰
T ^۳	۸.۰۰۰	۰.۰۰	.
T ^۴	۱۶.۰۰۰	.	.
T ^۵	۱۶.۰۰۰	۰.۰۰	۰.۰۰۰

Vitamin A was supplemented as vit. A acetate, ۱.۰۰% concentration, vitamin E was supplemented as dl- α -Tocopherole acetate, ۰.۰% concentration and selenium was supplemented as sodium selenite, ۴.۰% concentration (Multivita Company, Sixth of October governorate, Egypt). For all treatments, there were three replicate cages of three hens in each cage. Hens of all treatment groups had nearly similar initial average live body weight. The dimension of cage was ۴۰x۴۰x۴۰ cm. All hens were kept under the same managerial and hygienic conditions and they were exposed to ۱۶ hours of light per day and fed *ad-libitum*. Fresh and clean water during the whole experimental period. The experimental diet for all treatment groups was formulated to cover the nutrient requirements of laying hens as recommended by NRC (۱۹۹۴). The Composition and calculated analysis of the diet are presented in Table (۱).

Table (۱): Composition and calculated analysis of the experimental basal diet.

Ingredient	Quantity %
Yellow corn	۶۳,۱۴
Soybean meal (۴۴ %)	۲۷,۱۰
Di Calcium phosphate	۱,۰۰
Limestone	۷,۶۰
Vitamins and Minerals mixture*	۰,۳۰
NaCl	۰,۳۰
DI-Methionine	۰,۰۶
Total	۱۰۰,۰۰
Calculated analysis**	
Crude protein (%)	۱۶,۸۲
Metabolizable energy (kcal / kg diet)	۲۷۲۱,۷۰
Ether extract (%)	۲,۸۱
Available phosphorus (%)	۰,۴۱
Calcium (%)	۳,۲۷
Lysine (%)	۰,۹۰
Methionine (%)	۰,۳۶
Methionine + Cystine (%)	۰,۶۴

*Each ۳ kg of vitamins and mineral mixture contained: vit. A ۱۰.۰۰۰ IU; vit D^۳ ۲.۰۰۰ IU; vit E ۱۰ mg; vit K_۱ ۱.۰۰۰ mg; vit B_۱ ۱.۰۰۰ mg; vit B_۲ ۰.۰۰۰ mg; vit B_۳ ۱.۰۰۰ mg; vit B_۶ ۱۰ mg; Pantothenic acid ۱۰ mg; Niacin ۳۰ mg; Folic acid ۱.۰۰۰ mg; Biotin ۰.۰ mg; Choline ۳۰۰ mg; Manganese ۶۰ mg; Zinc ۰.۰ mg; Copper ۱۰ mg; Iron ۳۰ mg; Iodine ۱.۰۰۰ mg; Selenium ۱.۰۰ mg; Cobalt ۱.۰۰ mg; CaCO_۳ to ۳ gm.

**Calculated analysis according to NRC (۱۹۹۴).

At the end of the experiment, three hens were randomly selected from each treatment group. They were slaughtered and then their ovaries and spleens were removed from the body and subjected to the clinical examination and kept in formalin solution (10%) for histological study. After fixation, the specimens were dehydrated; cleared; embedded in paraffin wax and blocked. Sections of 6 microns thickness were cut using a rotary microtome then mounted and stained by Haematoxylin and Eosin stains (Carleton *et al.*, 1980). All sections were examined under light microscope and photographed using a digital camera.

RESULTS AND DISCUSSION

Histopathological Findings:

Most birds of the control group which received diet without vit. A, vit. E and selenium showed normal histological appearance of ovary and spleen. The former findings are illustrated in Figs. 1 and 2.

On the other hand, birds received diet containing 500 mg/kg diet of vit. E with 0.50 mg/kg diet of selenium revealed that the ovary was moderately activated with a presence of numerous primary oocytes (Fig. 3). The spleen showed moderate hyperplasia of the white pulp and focal thickening of the splenic capsule. The latter was infiltrated with round cells predominantly lymphocytes and macrophages (Fig. 4) sustaining to the observed improvement in white pulp of the spleen.

Moreover, birds fed diet containing 8000 IU/kg diet of vit. A and 500 mg/kg diet of vit. E showed moderate activation of ovarian follicles with hypercellular stroma and plumped stromal cells besides aggregation of leukocytes (Fig. 5). The spleen showed hyperplasia in the lymphoid cells of white pulp and an increase in the reticuloendothelial cells (REC) and hemosiderosis in the red pulp (Fig. 6). These findings confirm that the treatment improved the immunological function of the spleen.

Birds received diet containing 16000 IU/kg diet of vit. A showed slight increase in the primary and growing ova than control (Fig. 7). Some ova were fused together to form large cysts containing eosinophilic material surrounded by atrophied stroma. The spleen revealed moderate hyperplasia in the white pulp area (Fig. 8).

The birds received diet containing 16000 IU/kg diet of vit. A, plus 500 mg/kg diet of vit. E and 0.50 mg/kg diet of selenium showed active ovaries containing variable sized ova and numerous blood capillaries (Fig. 9). Also, focal hemorrhages may be noticed. The granulosa cells around these ova were vacuolated or showed eosinophilic granular cytoplasm. Some large ova may be degenerated to form a huge amount of eosinophilic material. The latter was rarely infiltrated with lymphocytes. The spleen showed hyperplasia of the white pulp. The wall of most blood vessels was thickened (Fig. 10).

In conclusion, it is concluded that the addition of vitamins A; E and Se to layer diets activated the ovarian function and enhanced the immune response of laying hens under heat stress conditions.

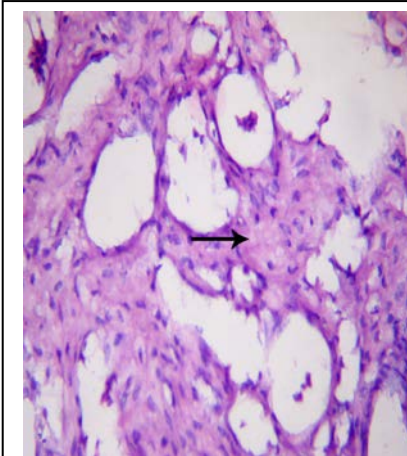


Fig. (1): T. S. in ovary of hen of the control group, showing normal structure of the growing follicles along with many secondary follicles (arrows), HE x 1200.

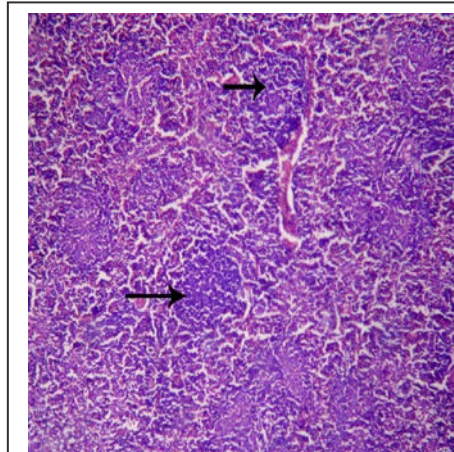


Fig. (2): T. S. in spleen of hen received control diet showing normal white and red pulp areas (arrows), HE x 200.

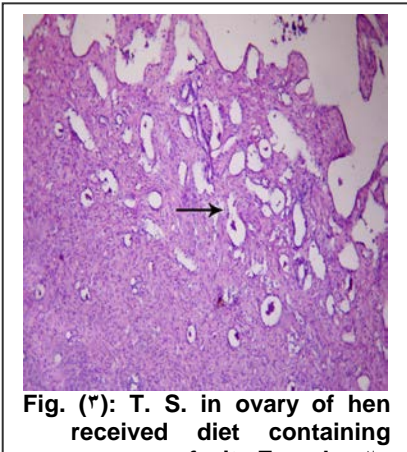


Fig. (3): T. S. in ovary of hen received diet containing 0.05 mg of vit. E and 0.25 mg of selenium/ kg diet showing an increase of primary oocytes (arrow), HE x 100.

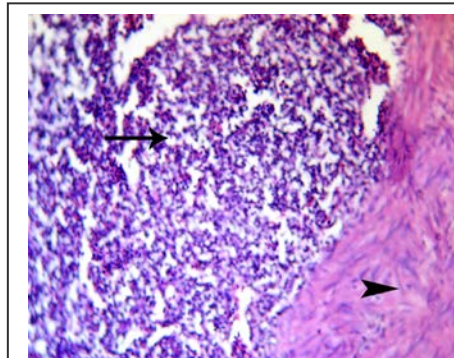


Fig. (4): T. S. in spleen of hen received diet containing 0.05 mg of vit. E and 0.25 mg of selenium/kg diet showing hyperplasia of white pulp (arrow) and focal thickening of the splenic capsule (arrowhead), HE x 1200.

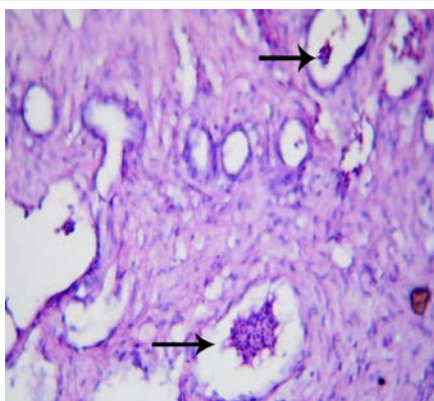


Fig. (٥): T. S. in ovary of hen received diet containing ٨٠٠٠ IU of vit. A and ٥٠٠ mg of vit. E/kg diet showing moderate activation of ovarian follicles with hypercellular stroma cells (arrows), HE x ١٢٠٠.

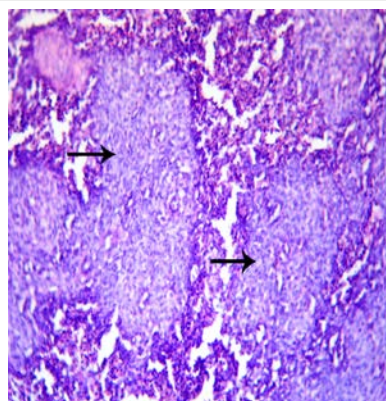


Fig. (٦): T. S. in spleen of hen received diet containing ٨٠٠٠ IU of vit. A and ٥٠٠ mg of vit. E/kg diet showing hyperplasia in the lymphoid cells of white pulp (arrows) and an increase in the REC, HE x ١٢٠٠.

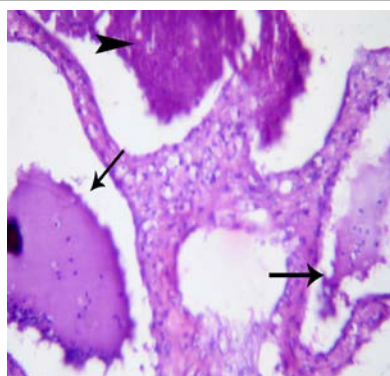


Fig. (٧): T. S. in ovary of hen received diet containing ١٦٠٠٠ IU/kg of diet of vit. A showing mature ova with huge amount of follicular materials (arrowhead), HE x ١٢٠٠.

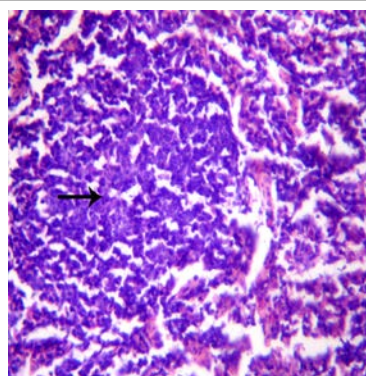
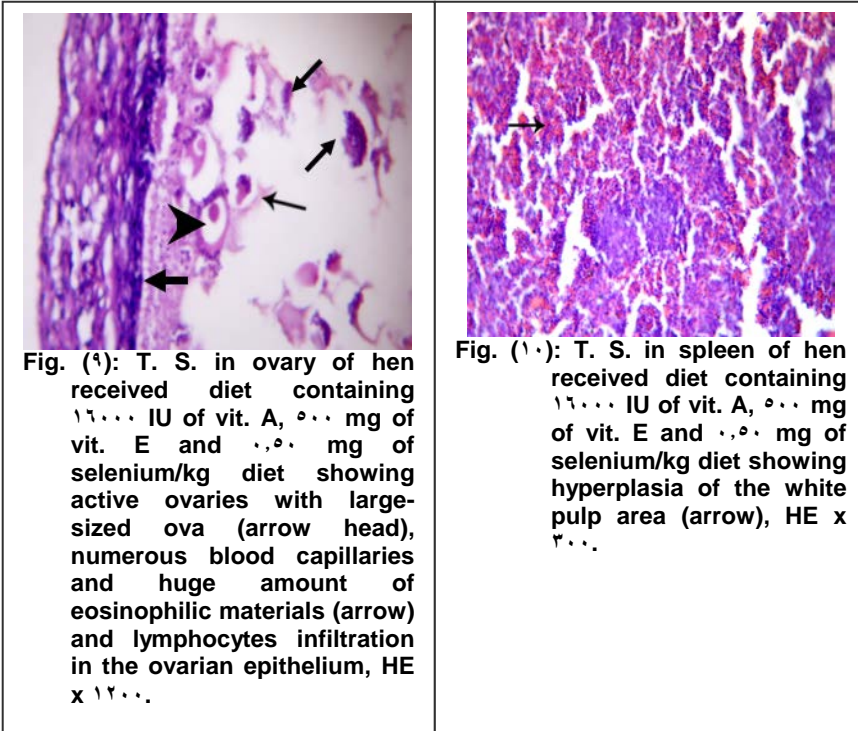


Fig. (٨): T. S. in spleen of hen received diet containing ١٦٠٠٠ IU/kg of diet of vit. A showing moderate hyperplasia in the white pulp area (arrow), HE x ١٢٠٠.



REFERENCES

- Butera, S. T. and S. Kraowka (1986). Assessment of lymphocyte function during vitamin A deficiency. *Am. J. Vet. Res.* 47: 800-800.
- Carleton, R. A.; B. Dury and E. A. Wallington. (1980). *Histological Technique for Normal and Pathological Tissue and Identification of Parasites*. Fifth Edition, Oxford Univ. Press, New York, Toronto.
- Chan, K. M. and E. A. Decker (1994). Endogenous skeletal muscle antioxidants. *Crit. Rev. Food Sci. Nutr.*, 34: 403 - 426.
- Charles, D. R. (2002). Responses to the thermal environment. In: *Poultry Environment Problems, a Guide to Solutions* (Charles, D. A. and Walker, A. W. Eds.) Nottingham University Press, Nottingham, United Kingdom, pp. 1-16.
- Daniels L. A. (2004). Selenium: does selenium status have health outcomes beyond overt deficiency? *Med. J. Aust.*, 180(8): 383 - 386.
- Grizzle, J.; M. Iheanacho; A. Saxton and J. Broaden (1992). Nutritional and environmental factors involved in egg shell quality of laying hens. *Br. Poult. Sci.* 33: 781-794.
- Lin, H.; H. C. Jiao; J. Buyse and E. Decuyper (2006). Strategies for preventing heat stress in poultry. *World's Poultry Science Journal.* 62: 71-80.

- Lin, H; L. F. Wang; J. L. Song; Y. M. Xie and Q. M. Yang (2002). Effect of dietary supplemental levels of vitamin A on the egg production and immune responses of heat-stressed laying hens. *Poult. Sci.* 81: 458-460.
- Mahmoud, K. Z.; M. M. Beck; S. E. Scheideler; M. F. Forman; K. P. Anderson, and S. D. Kachman (1996). Acute high environmental temperature and calcium-estrogen relationship in the hen. *Poult. Sci.* 75:1000-1002.
- Mashaly, M. M.; G. L. Hendricks; M. A. Kalama; A. E. Gehad; A. O. Abbas and P. H. Patterson (2004). Effect of heat stress on production parameters and immune responses of commercial laying hens. *Poult. Sci.* 83:889-894.
- McDowell, L.R. (1989). Vitamins in Animal Nutrition-Comparative Aspects to Human Nutrition .In: McDowell LR (ed.). Vitamin A and E London: Academic Press. p. 93-131.
- NRC (1994). Nutrient Requirements of Poultry. 9th rev. ed. National Academy Press, Washington, DC.
- Puthongsiriporn, U.; S. E. Scheideler; J. L. Shell, and M. M. Beck (2001). Effect of vitamin E and C supplementation on performance, in vitro lymphocyte proliferation and antioxidant status of laying hens during heat stress. *Poult. Sci.* 80:1190-1200.
- Rayman, M. P. (2002). The argument for increasing selenium intake. *Proc. Nutr. Soc.* 61:203-10.
- Sahin, K. and O. Kucuk (2001). Effects of vitamin C and vitamin E on the performance, digestion of nutrients and carcass characteristics of Japanese quails reared under chronic heat stress (32°C). *J. Anim. Physiol. Anim. Nutr.* 85, 230-231.
- Sahin, K.; N. Sahin; M. Sari and M. F. Gursu (2002). Effects of vitamin E and A supplementation on lipid peroxidation and concentration of some mineral in broilers reared under heat stress (32°C). *Nutrition Research.* 22: 723-731.
- Schwarz, K. and C. Foltz (1957). Selenium as an integral part of factor 3 against dietary necrotic liver degeneration. *J. Am. Chem. Soc.* 79: 3292.
- Spears, J. W. (1999). Reevaluation of the metabolic essentiality of the minerals. Review. *Asian Australasian Journal-of Animal Sciences.* 12 : 1002 - 1008.
- Tengerdy, R. P. (1988). Vitamin E, immune response and disease resistance. *Ann. NY Acad. Sci.* 570: 330-344.
- Yu, B. P. (1994). Cellular defenses against damage from reactive oxygen species. *Physiol. Rev.* 74: 139 - 162.

بعض المشاهدات الهستولوجية للمبيض والطحال في الدجاج البياض المُجهَد
حرارياً المُعامل بمضادات الأوكسدة
محمد عزت عبد الحق ، شريف محمد سنبل ، علي عبد الرازق عسکر و
خالد محمد محروس
قسم الدواجن- كلية الزراعة- جامعة الزقازيق

أجريت هذه التجربة لدراسة أثر استخدام مستويات مختلفة من فيتامين أ و فيتامين هـ والسيلينيوم على نسيجي المبيض والطحال للدجاج البياض تحت ظروف الإجهاد الحراري، وقد تم استخدام ٤٥ دجاجة من دجاج البوفينز البياض على عمر ٤٢ أسبوع وتم توزيعها عشوائياً إلى ٥ مجموعات تجريبية باستخدام مستويات مختلفة من فيتامينات أ و هـ وكذلك السيلينيوم. أظهرت نتائج الفحص الهستولوجي نشاطاً واضحاً في المبيض وكذلك زيادة في عدد الحويصلات المبيضية في الطيور التي أضيف إلى علائقها (٥٠٠ ملجم فيتامين هـ/ كجم علف + ٠,٢٥ ملجم سيلينيوم/ كجم علف)، كما أظهر الطحال نشاطاً في منطقة اللب الأبيض وزيادة موضعية في سمك جداره. أما الطيور التي أضيف لعلائقها (٨٠٠٠ وحدة دولية فيتامين أ/ كجم علف + ٥٠٠ ملجم فيتامين هـ/ كجم علف) فقد أظهرت أيضاً نشاطاً في المبيض وكذلك زيادة في عدد الخلايا الليمفاوية والإلتهامية في الطحال. و أدت إضافة (١٦٠٠٠ وحدة دولية فيتامين أ/ كجم علف) للعليقة إلى زيادة طفيفة في عدد الحويصلات المبيضية الإبتدائية والنامية، في حين أدت هذه الإضافة إلى زيادة في عدد خلايا اللب الأبيض بالطحال. وأخيراً فإن المجموعة التي عوملت بخليط من (١٦٠٠٠ وحدة دولية فيتامين أ/ كجم علف + ٥٠٠ ملجم فيتامين هـ/ كجم علف + ٠,٢٥ ملجم سيلينيوم/ كجم علف) قد أظهرت مبيضاً نشطاً يحتوي على أحجام مختلفة من الحويصلات المبيضية في مراحل النمو المختلفة، كما لوحظ أيضاً زيادة واضحة في عدد الخلايا في منطقة اللب الأبيض بالطحال.

من هذه الدراسة يتضح أن إضافة كلاً من فيتامين أ، فيتامين هـ والسيلينيوم إلى علائق الدجاج البياض أدت إلى تنشيط وظائف المبيض وكذلك تحسين الاستجابة المناعية للدجاج البياض تحت ظروف الإجهاد الحراري.

قام بتحكيم البحث

كلية الزراعة – جامعة المنصورة
كلية الزراعة – جامعة عين شمس

أ.د / ترك ابراهيم دره
أ.د / ابراهيم الورداني السيد حسن