

EGFR GENE EXPRESION IN CANCER BREAST PATIENTS AND ITS CORRELATION WITH CLINICO PATHOLOGIC PARAMETERS

Mahmoud Moawad⁽¹⁾Tarek A..Salem⁽²⁾E.A.EL-Absawy⁽²⁾H.N.Tawfiek ⁽¹⁾S.H.Hassanien⁽²⁾

1. Department of Surgical Pathology,National Cancer Institute,Cairo University.

2. Molecular Biology, Genet. Eng. & Biotechnol. Inst., Minufiya Univ.;; Egypt.

ABSTRACT

Breast carcinoma ranks as first malignancy affecting females, contributing 33% of all female cancers. EGFR a class of oncogenes prevalent in breast cancer and play a role in cancer development. This research was performed to assess EGFR expression using immunohistochemical (IHC) staining. These marker was studied in 50 breast female cancer patients by IHC Technique. Define their relation to various clinical and other prognostic markers and correlate their expression to each other. The results of this study was that EGFR gene amplification, by immunohistochemistry was positive in 66% of invasive duct breast cancer and showed the EGFR was significantly associated with bad prognostic markers as lymph nodes involvement and absence of Estrogen and progesterone receptors.

KEYWORDS: Cancer breast, EGFR - IHC

INTRODUCTION

Breast cancer is ranking number one after urinary bladder tumors and malignant lymphomas at National Cancer Institute (NCI), Cairo University in Egypt. Breast carcinoma constitutes 33% of all females' cancers in Egypt (El-Bolkainy et al., 2010). Prognostic factors identify patients at higher or lower risk of breast cancer recurrence or death. Useful prognostic factors can be applied broadly to large, heterogeneous patient groups (Kathy and Miller, 2000). Immunohistochemistry (IHC)

techniques are widely used in diagnostic histopathology to help re-differentiate the light microscopically undifferentiated tumors (Ross and Fletcher, 2000). Estrogen and Progesterone are well established steroid endocrine regulators. Estrogen promotes breast epithelial cell proliferation, development as progesterone (Greene et al., 2004). Expressions of the epidermal growth factor receptor (EGFR) have been shown to be adverse prognostic factors in mammary carcinoma. EGFR, C-erbB-2, C-erbB-3 and C-erbB-4 (alternatively, authors use the HER terminology (HER1-4), are class of oncogenes prevalent in several solid tumors. They play an important role in breast cancer development and in regulating cell growth, survival and differentiation in a complex manner. Receptor heterodimerization between cell surface HER receptor monomers form homodimers with the same receptor or heterodimers with other members of the HER family in response to ligand binding (William and Gregory 2009). The aim of this investigation was to study of histopathological parameters using light microscopy in breast cancer cases, immunohistochemical (IHC) analysis of estrogen, progesterone receptors in breast cancer cases, assessment of EGFR gene expression by IHC and Correlate their expression to each other in newly diagnosed female cancer patients.

MATERIALS AND METHODS

Patients

The present study was performed on 50 diagnosed female breast cancer patients presented to surgical Department, National Cancer Institute (NCI), Cairo University, during the period from 2008 to 2011. Their ages ranged from 27 to 60years old. The fresh tumor tissues were fixed in 10% neutral buffered formalin (18 to 24 hours), and processed for histological and immunohistological analysis from paraffin embedded tissues.

Histological diagnosis

For histological diagnosis, tissues were fixed in 4% phosphate-buffered formalin and routinely processed to wax. Paraffin sections (5 µm) were stained with heamatoxilene and eosin and examined with the microscope. (Bancroft and Gamble, 2002).

Immunostaining

Estrogene receptors (ER) and progesterone receptors (PgR) were detected using an improved Biotin-Streptavidin Amplified (B-SA) detection system (Taylor and Kledzik, 2002). The over expression of EGFR protein was examined immunohistochemically using autostainer machines. EGFR was categorized into negative showing Homogenous or heterogenous tumour membrane and cytoplasm immunoreactivity was utilized to indicate tumour EGFR-expression (Park et al., 2005).

RESULTS AND DISCUSSION

Histology

Light microscope was used to study the cases of malignant breast lesions, from invasive ductal carcinoma of the breast by hematoxelin and eosin stain (Fig. 1). Malignant cells and high level of mitotic division were observed. **Table 9. Correlation between EGFR by immunohistochemistry and estrogen, progestron receptors.**

Immuno parameters		EGFR by IHC				Total	P value
		+ve		-ve			
		No	%	No	%		
ER	+ve	14	44	18	56	32	(p<0.001)**
	-ve	13	72	5	28	18	
PR	+ve	9	35	17	65	26	(p=0.022) *
	-ve	18	75	6	25	24	



Fig. (1). Histology study. (a) A case of IDC by hematoxylin and eosin stain (X 400) showing mitosis.

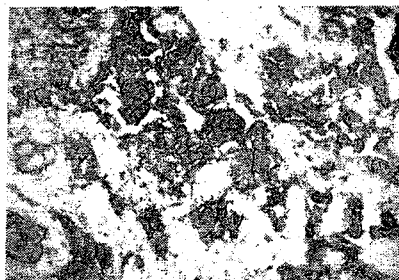


Fig. (2). IDC Showing strong expressing membranous reaction immunostaining of EGFR X400

Correlation between EGFR by immunohistochemistry and estrogen, progesteron receptors

Table (1) shows. Direct statically significant association was detected between EGFR (Fig.2) and estrogen receptors (ER) expression (P value<0.001**), and progesterone receptor (P value<0.022*) by immunohistochemistry. The material of this work comprised tumor tissue obtained from 50 diagnosed female breast cancer patients presented to the surgical Department, NCI, and Cairo university.during period from 2008 to 2011.Their age ranged from 27 to 60 with a mean of 44.74 ± 1.432 , median of 44 years. They underwent surgery either in the form of conservative wide local excision and axillary lymph node dissection or modified radical mastectomy. In this work EGFR expression was determined in 50 newly diagnosed female breast cancer patients with invasive duct carcinoma, trying to correlate such markers with prognostic

markers. The mean age of female patients reported in this study was 44.74 years. This was in agreement with results reported by other studies on Egyptian females cancer patients, as those described by El Bolkainy et al., (2010) reported that a mean age of 46.9 years. Western studies reported a mean age of 57 years by Henerson, (2008). However these figures are about 10 years lower than those mentioned by researchers in western countries. Gasparini, (2009), and Chaprin et al., (2009) reported that a mean age of 56.60 and 56.7 years respectively among breast cancer patients. As shown in the results; all cancer cases were IDC the most common histopathological type of cancer breast as it represents 70% of all breast cancer in Western countries and 85.02% in Egypt NCI series (Mokhtar et al., 2007). In the present study, malignant breast tissues invasive duct carcinoma by Hematoxelin and Eosin stain showed groups and clusters of malignant ductal cells, of highly anaplasia and mitosis. This was in agreement with El-Bolkainy et al., (2010). In this work expression of EGFR by IHC method was 66% in breast cancer cases. Anwar et al., (2000), who worked on 36 Egyptian female patients with IDC breast cancer by IHC, reported a lower incidence being 66.6%. Moreover the incidence recorded by Western authors an incidence of 55% was reported by Tsutsui et al., (2009). In this study, no correlation could be found between EGFR expression and the age of breast cancer patients. The highest expression of EGFR among our patients was encountered in patients below 50 years (70%) and above 50 years (66%). While the percentage among patients of age less than 30 years was 25% only. But the differences were not statistically significant which could be attributed to the low number of the different age subgroups. Study of larger number of breast cancer patients could underline the impact of age as being one of the most important predictors of breast cancer progression and metastasis (Bhargava et al., 2005). Similarly to our results, and Bouter et al., (2007), found no correlation between EGFR expression and age. EGFR expression was inversely associated with the ER & PR status. This was in concordance with Steinman et al., (2007), Zhang et al., (2011) who reported that the lack of expression of EGFR

correlated with high levels of steroids receptors and vice versa. So EGFR expression could be considered as one of the favourable prognostic markers in cancer breast being inversely associated with ER and PR status .

REFERENCES

- Anwar, N.; Mokhtar, N.; Mourad, M. and Dahaba, N. (2000). c-erbB-1 and its relation to lymph node positivity on Egyptian Breast cancer patients. *CMB* 1:325-329.
- Bancroft, JD. and Gamble, M. (2002). *Theory and Practice of histological techniques*, Fifth Edition; Elsevier science limited, Pp 689-691.
- Bhargava, R.; Gerald, W.; Li, A.; Ladanyi, M. and Chen, C. (2005). EGFR gene amplification in breast cancer: correlation with epidermal growth factor receptor mRNA and protein expression and HER-2 status and absence of EGFR-activating mutations, *Modern Pathology J* . 18, 1027-1033.
- Bouter, A.; Zanden, R.; Siccama, I.; Wall, E. and Diest, P. (2007). Distinction between hereditary and sporadic breast cancer on the basis of clinicopathological data, *J Clin Pathol*; 59:611-617.
- Chaprin, C.; Vielh, P.; Andrac, L. and Piana, L. (2009). P-glycoprotein in breast Ca. *J. Natl. Cancer Inst.*, 82 (10): 2542-52.
- El-Bolkainy, M.; Noh, A. and El-Bolkainy, T. (2010). *Breast cancer in topographic pathology of cancer*, 3rd Edition. Al-Asdekaa Graphics Center Cairo, pp 81-88.
- Gasparini, G. (2009). Clinical significance of determination of surrogate markers of angiogenesis in breast cancer. *oncol, Hematol*, 37: 97-114.
- Greene, G.I.; Sobel, N.B.; King, W.J. and Jenser, A.V . (2004). Immunohistochemical studies of estrogen receptors. *J Steroid Biochem*. 20: 51-56.
- Henerson, R.; Peterse, J. and Millis, R. (2008). Invasive duct carcinoma pathological correlation. *Semin Diagn Pathol J*, 11: 181-192.

Kathy, D. and Miller, M.D. (2000). San Antonio Breast Cancer Symposium, prognostic crystal Ball in Search of powerful predictors. *Br. J. Cancer* 29(3): 1113-1120.

Mokhtar, N.; Goda, I. and Adel, I. (2007). Cancer pathology registry 2003-2004. published by the Department of Pathology, National Cancer Institute, Cairo university. Egypt.

Park ,S.S.; Kim,Y.A.; Kim,J.E.; Kim,Y.C. and Kim,S.W.(2005). Caveolin-1 is down – regulated and inversely correlated with HER2 and EGFR exepression status in invasive ductal carcinoma of the breast.*Histopatology*, 47: 625-630.

Ross, J.S. and Fletcher, J.A. (2000). The HER2/neu oncogene in breast cancer: prognostic factor, predictor factor and target for therapy. *Stem Cell*, 16: 413-428.

Steinman,S.; Wang,J.; Bourne,P.; Yang,Q. and Tang,P.(2007). Expression Cytokeratin Markers, ER-alpha, PR, HER-2/neu, and EGFR in Pure Ductal Carcinoma In Situ (DCIS) and DCIS with Co-existing Invasive Ductal Carcinoma (IDC) of the Breast. *Annals of Clinical & Laboratory Science*, vol. 37, no. 2, 127- 134.

Taylor, C.R. and Kledzik, G. (2002). Immunohistologic techniques in surgical pathology, a spectrum of new special stains. *Hum. Pathol.*, 12 (7): 590-596.

Tsutsui, S.; Ohno, S.; Murakami, S. and Kataoha, A. (2009). C-erbB-2 between primary and recurrent breast cancer. *Int. J. Cancer*, 70: 7321-7330.

William, B. and Gregory, J. (2009). The molecular basis of human disease, New York, pp 101-120.

Zhang,X.T.; Kang,L.G.; Ding,L.; Vranic,S.; Gatalica,Z. and Wang,Z.(2011). A positive feedback loop of ER-a36/EGFR promotes malignant growth of ER-negative breast cancer cells. *Oncogene* (2011) 30, 770–780.

التعبير الجيني لمستقبلات معاملى نمو النسيج الطلائى فى مرضى سرطان الثدي وعلاقتهم
بالعوامل الاكلينيكية الباثولوجية

(١)محمود معوض (٢) طارق عبدالرءوف سالم (٢) السيد عبد الخالق العيساوى (١) حسن
نبيل توفيق محمد (٢)السيد حسن حسانيين

١-قسم الباثولوجى - معهد الأورام - جامعة القاهرة

٢-قسم البيولوجيا الجزيئية-معهد الهندسة الوراثية- جامعة المنوفية

يعتبر سرطان الثدي فى المرتبة الأولى بالنسبة لجميع أنواع السرطانات الاخرى فى جمهورية مصر العربية وذلك من واقع سجلات المعهد القومى للأورام- جامعة القاهرة. تم دراسة مستقبلات معاملى نمو النسيج الطلائى بطريقة الصبغات المناعية ومقارنته بالعواملى الهستوباثولوجيه ومستقبلات هرمون الاستروجين والبروجسترون فى ٥٠ سيدة مصابة بسرطان الثدي ، تتراوح اعمارهن بين ٢٧-٦٠ عاما بمتوسط قدره حوالى ٤٤ عاما. تبين من هذه الدراسة وجود مستقبلات معاملى نمو النسيج الطلائى بطريقة الصبغات المناعية بنسبة ٦٦% فى مرضى سرطان الثدي . وقد تبين ايضا وجود علاقة مباشرة بين وجود مستقبلات معاملى نمو النسيج الطلائى ووجود المرض بالعدد اليمفاوية مع غياب مستقبلات هرمون الاستروجين والبروجسترون المناعية